

**Last updated on 2019-12-18**

## **European Board of Head and Neck Radiology Diploma Guidelines**

### **Aim(s) and target group**

The diploma introduced by ESHNR since 2009 is the common European qualification for head and neck radiology specialists and will help to standardise training and expertise in head and neck imaging subspecialisation across Europe. The ESHNR Diploma has been endorsed by the European Society of Radiology (ESR) since 2011.

The European Board in Head and Neck Radiology Diploma is a document certifying an in-depth knowledge of the pertinent anatomy, pathology and imaging-related issues in the field of head and neck and maxillo-facial and dental radiology as defined in Appendix 1 and in the Head and Neck Subspecialty (Level III) Curriculum of the ESR, going beyond the requirements included in the European General Radiology Curriculum.

This diploma represents a recognised qualification in head and neck imaging subspecialisation and will assist head and neck radiologists in the promotion of their skills and experience when dealing with other clinical colleagues as well as the general public. The candidates are fully-trained, licensed and practicing radiologists who have completed at least 5 years of general radiology training and have a European radiology qualification diploma or the equivalent of a European radiology diploma.

### **Fee structure**

Examination handling fee:

400.00 € ESHNR Active Members

800.00 € ESHNR Corresponding Members

In case a candidate does not pass the European Board of Head and Neck Radiology Diploma, the candidate may apply again, in order to retake the examination. No reduced fee for re-examination will be granted.

### **Eligibility criteria**

Eligible for the European Board in Head and Neck Radiology are radiologists who:

- Have completed at least 5 years of general radiology training and have a European radiology qualification diploma or the equivalent of a European radiology diploma

- Fulfil the criteria of the Level III subspecialty curriculum in head and neck radiology as outlined in the official ESR training curriculum booklet
- Can provide proof of at least 100 hours of postgraduate teaching as outlined in Appendix 2
- Are members of the ESHNR and ESR
- No restriction on nationality and country of training.

## Application steps

Candidates applying for the European Board in Head and Neck Radiology Diploma need to:

- Fulfil the eligibility criteria
- Acquire a total amount of at least 100 points by:
  - Attending different national or international meetings or courses/workshops in head and neck radiology including the ESHNR educational webinars. If the courses/meetings/workshops do not deal exclusively with head and neck radiology, a detailed list of the lectures attended by the candidate should be provided (e.g. if in a 5 day international meeting, there are only 10 hours on head and neck radiology, only these 10 hours give 10 points (1 hour = 1 point))
  - Overall the candidate is required to attend courses covering 5 of the 8 sub-fields of the head and neck as described in the Appendix 1.
  - Attending at least one annual meeting of the ESHNR (the only attended ESHNR Annual Meeting can be the meeting where the candidate sits the exam).
  - Presenting a paper or a poster at the ESHNR meeting or by publishing a paper in a peer-reviewed journal as first author, second author or last author
  - Attending the ESHNR-ESOR Exchange Fellowship Programme (100 points)
- Provide to the ESHNR Office ([office@eshnr.eu](mailto:office@eshnr.eu)) the following documents:
  - Application form
  - CV
  - Copy of the diploma certifying that the applicant is a medical doctor
  - Copy of the diploma certifying that the applicant has a European radiology qualification diploma or the equivalent of a European radiology diploma
  - Letter of certification of the Chairman of the Department where the trainee comes from
  - Copy of the certificate of attendance of one Annual Meeting of the ESHNR (if the candidate has not yet attended one annual ESHNR meeting, he/she has to provide a proof of inscription to the meeting; the diploma will be awarded only upon successful examination and confirmation of attendance at the annual ESHNR meeting)
  - Copy of the certificate of attendance of all meetings, courses, exchange programmes or presented posters/oral presentations as well as published papers
  - Certification of having performed and passed the European radiology qualification diploma or the equivalent of a European radiology diploma

- Pay the application fee (400.00 € Active members; 800.00 € Corresponding members)

## Diploma acquirement

Awarding the European Board in Head and Neck Radiology Diploma will be decided upon by the Educational Board of the ESHNR depending on the results obtained in the written and oral examination and will be validated by the Executive Committee of the ESHNR once the candidate has fulfilled all above-mentioned criteria.

The European Board in Head and Neck Radiology Examination takes place twice per year. The first examination session is in Spring at the ECR in Vienna and the second session takes place at the Annual Meeting of the ESHNR in Autumn. The examination includes a written and an oral part (see below). The candidate must pass both oral and written parts.

## Examination results

All candidates will be notified about the results of the examination at the latest 7 days after the examination. The candidates who have passed the examination will receive the European Board in Head and Neck Radiology Diploma document by regular mail within 4 weeks after sitting the examination. All candidates who have passed the examination will also receive the Fellowship certificate of the ESHNR during the awards ceremony of the Annual Meeting.

## Diploma validity and renewal

The European Board in Head and Neck Radiology Diploma is valid for 5 years.

ESHNR will renew the European Board in Head and Neck Radiology Diploma every five years for full ESHNR and ESR members in good standing upon proof of at least 100 CME credits in Head and Neck Radiology within 5 years. Attendance of at least one ESHNR Annual Meeting within that period is mandatory.

A renewal fee of € 30.00 will be due.

## Knowledge base

Candidates applying for the European Board in Head and Neck Radiology Diploma need:

- To have an in-depth knowledge of the normal anatomy of the head and neck, including the skull base, paranasal sinuses, the oral cavity, pharynx and larynx, the middle and inner ear, salivary glands, thyroid and parathyroid glands, thoracic inlet,



**eshnr**

european society of  
head and neck radiology

orbit, teeth, mandible and temporomandibular joint, arterial and venous system, and the neck including deep spaces and compartments

- To have a good knowledge of congenital lesions of the head and neck, including paranasal sinuses, oral cavity, pharynx and larynx, middle and inner ear, skull base, orbit, teeth, temporomandibular joint, thyroid and parathyroid, salivary glands, neck and thoracic inlet
- To have an in-depth knowledge of common and less common diseases of the eye and orbit, temporal bone and skull base, paranasal sinuses, thyroid, parathyroid and salivary glands, maxillo-facial trauma, infection, inflammation and tumors and disorders of the teeth, imaging manifestations of lesions and abnormal function of the temporomandibular joint and mandible, pharynx and larynx, lymph nodes, vessels and soft tissues in the head and neck, and thoracic inlet including the brachial plexus
- To be aware of the role of radionuclide imaging in disorders of the thyroid and parathyroid glands and in the functional evaluation of endocrine abnormalities
- To be aware and understand the role of PET/CT in oncologic diseases and to understand common manifestations of head and neck tumors on hybrid imaging modalities
- To have an in-depth knowledge role of ultrasound- and/or CT-guided puncture of salivary glands, lymph nodes and the thyroid gland
- To have an in-depth knowledge of the role, advantages and disadvantages of CT, ultrasound, Cone beam CT, videofluoroscopy and MRI applications in the head and neck
- To have an in-depth knowledge of the normal anatomy of the arterial and venous system and its relevance to interventional radiology

Concerning **normal anatomy**, candidates should have an in-depth knowledge of:

- The temporal bone, facial skeleton, skull base, cranial nerves, orbits and visual pathways
- Sinuses, pharynx, oral cavity, mandible, teeth, temporomandibular joints, salivary glands, larynx, neck
- Deep spaces of the face and neck, thoracic inlet and brachial plexus, as well as the thyroid gland and parathyroid glands

Furthermore, candidates should be able:

- To describe normal variants of the temporal bone, facial skeleton, skull base, cranial nerves, orbits and visual pathways, sinuses, pharynx, oral cavity, mandible, teeth, temporomandibular joints, salivary glands, larynx, neck, deep, spaces of the face and neck, thoracic inlet and brachial plexus, as well as the thyroid gland and parathyroid glands and to differentiate these from disease
- To describe the terminology for describing the site of lymph nodes in the head and neck region.

**European Society of Head and Neck Radiology**

Am Gestade 1 | 1010 Vienna | Austria

Phone: +43 1 5334064-918 | E-mail: [office@eshnr.eu](mailto:office@eshnr.eu)

[www.eshnr.eu](http://www.eshnr.eu) | ZVR 421925549

Concerning the **temporal bone**, candidates should be able:

- To list and to describe common and uncommon imaging features of congenital disorders leading to deafness (e.g. cochlear aplasia/hypoplasia, Mondini malformation, large endolymphatic sac anomaly (LESA) / large vestibular aqueduct syndrome (LVA))
- To describe the imaging features and clinical features of disorders leading to secondary deafness including otosclerosis, Menière's disease, temporal bone inflammatory disease, and tumors of the cerebellopontine angle
- To confidently delineate the course of the facial nerve in its different components
- To describe the imaging and clinical features of tumors of the temporal bone and cerebello- pontine angle and to distinguish these from each other
- To describe the imaging and clinical features of traumatic lesions and fractures of the temporal bone
- To describe the imaging and clinical features of cholesteatoma
- To differentiate different pathologies of the external auditory canal, including atresia and tumorous lesions
- To differentiate different pathologies of the middle ear
- To be familiar with the different types of cochlea implants and their respective MRI compatibility / non-compatibility (including specific precautions)
- To list the various causes of vascular tinnitus and to describe their respective imaging features.

Concerning the **facial skeleton, skull base and cranial nerves**, candidates should be able:

- To list the different neoplasms of the clivus and to describe their respective imaging appearance, including meningioma, macroadenoma, chordoma, chondrosarcoma and others
- To describe the imaging and clinical features of lesions of the jugular foramen, including glomus tumour / paraganglioma, jugular bulb pseudolesions, jugular bulb diverticulum, dehiscent jugular bulb, jugular foramen schwannoma, jugular foramen meningioma and others
- To describe the imaging features and clinical features of diffuse diseases of the skull base, including fibrous dysplasia, plasmocytoma, Langerhans cell histiocytosis, chondrosarcoma and metastases
- To describe the normal anatomy and function of the cranial nerves and to list common and less common pathologies
- To list and categorize traumatic lesions of the facial skeleton and skull base and to be familiar with complications and therapeutic consequences
- To describe the typical imaging features of neoplasms of the mandible and maxilla
- To understand the imaging features of jaw lesions including cysts and cyst-like lesions

- To understand the imaging features of infectious and inflammatory lesions of the mandible, maxilla and skull base, including osteomyelitis, osteoradionecrosis, bisphosphonate osteonecrosis.

Concerning the **orbit and visual pathways**, candidates should be able:

- To describe the imaging and clinical features of congenital lesions of the orbit, including coloboma
- To describe the imaging and clinical features of typical tumours of the orbit in children including dermoid and epidermoid cysts, cavernous haemangioma, lymphangioma, rhabdomyosarcoma and retinoblastoma
- To describe the orbital manifestations of neurofibromatosis type I
- To describe the imaging and clinical features of infectious and inflammatory disorders of the orbits including optic neuritis, abscesses, sarcoidosis and idiopathic inflammatory disorders
- To describe the imaging and clinical features of benign tumours of the orbits in adults including meningioma, optic/chiasmal glioma, orbital haemangioma, and benign mixed tumour of the lacrimal gland
- To describe the imaging and clinical features of malignant tumours of the orbits in adults including ocular melanoma, orbital lymphoma, higher grade optic / chiasmal glioma, adenoid cystic carcinoma of the lacrimal glands.

Concerning the **nose, nasopharynx and paranasal sinuses**, candidates should be able:

- To describe the imaging and clinical features of congenital lesions of the paranasal sinuses including choanal atresia and frontoethmoidal encephalocele
- To differentiate normal variants of the nose and paranasal sinuses from pathology
- To describe the imaging and clinical features of infectious and inflammatory disorders of the nose and paranasal sinuses including acute and chronic rhinosinusitis, fungal sinusitis, sinonasal polyposis, sinonasal mucocele and sinonasal Wegener granulomatosis
- To be knowledgeable of typical complications of infectious and inflammatory disorders of the nose and paranasal sinuses
- To list and describe the typical surgical approaches to the nose and paranasal sinuses including functional endoscopic sinus surgery (FESS)
- To describe the imaging and clinical features of benign and malignant neoplasms of the nose and paranasal sinuses including inverted papilloma, juvenile angiofibroma, sinonasal hemangioma, sinonasal osteoma, sinonasal fibrous dysplasia, sinonasal squamous cell carcinoma, sinonasal adenocarcinoma, sinonasal melanoma, esthesioneuroblastoma, sinonasal lymphoma and others
- To describe the typical imaging features of the nose and paranasal sinuses after surgery
- To describe the imaging features and clinical features of the nasopharyngeal pathologies including Thornwaldt cyst, inflammatory and infectious lesions and neoplasms

Concerning the **masticator space, parotid space and carotid space**, candidates should be able:

- To describe the anatomical delineations of the masticator space, parotid space and carotid space
- To describe pseudolesions of the masticator space, including denervation atrophy, benign muscle hypertrophy and asymmetries of the pterygoid venous plexus
- To describe the typical and rare imaging features of abscess formations of the masticator space
- To describe the imaging features and clinical features of benign and malignant neoplasms of the masticatorspace including peripheral nerve sheath tumours of the trigeminal nerve
- To describe the imaging features and clinical features of infectious and inflammatory lesions of the parotidspace including parotitis, Sjogren syndrome and benign lymphoepithelial lesions in patients with HIV
- To describe the imaging features and clinical features of benign and malignant neoplasms of the parotid space including Warthin tumour, benign mixed tumour, adenoid cystic carcinoma, mucoepidermoid carcinoma, lymphoma, lymph node metastases and malignant tumors of the skin
- To describe the imaging features and clinical features of vascular lesions of the carotid space including ectatic carotid arteries, carotid artery pseudoaneurysm, carotid artery dissection, and jugular venous thrombosis
- To describe the imaging features and clinical features of neoplasms of the carotid space including carotid body paraganglioma, glomus vagale paraganglioma, schwannoma, and neurofibroma.

Concerning the **lymph nodes of the head and neck region**, candidates should be able:

- To have an in-depth understanding of the nomenclature of the lymph nodes and nodal regions
- To describe the imaging features and clinical features of infectious and inflammatory disorders of the lymph nodes including reactive lymph node enlargement, suppurative lymph nodes, Kimura disease, Castleman disease and others
- To describe the imaging features and clinical features of neoplastic disorders of the lymph nodes, including lymphoma (Hodgkin and Non-Hodgkin) and nodal metastases

Concerning the **oral cavity, oropharynx and retropharyngeal space**, candidates should be able:

- To describe the imaging features and clinical features of congenital lesions of the oral cavity and oropharynx, including dermoid and epidermoid cysts, accessory salivary tissue, lymphangioma and lingual thyroid gland
- To describe the imaging features and clinical features of inflammatory and infectious lesions of the oral cavity and oropharynx, including abscesses, retention cysts, sialoceles, sialadenitis and ranula
- To describe the imaging features and clinical features of benign and malignant neoplasms of the oral cavity and oropharynx, including benign mixed tumours, squamous cell carcinoma, malignant tumours of the minor salivary glands
- To describe the typical imaging features and clinical presentation of retropharyngeal abscesses.

Concerning the **hypopharynx, larynx and cervical esophagus**, candidates should be able:

- To describe the imaging features and clinical features of neoplasms of the hypopharynx and larynx, including squamous cell carcinoma of the hypopharynx, of the supraglottic, glottic and subglottic regions, chondrosarcoma and other malignant tumors of the larynx
- To describe the typical imaging features of the hypopharynx and larynx after surgery and after radiation
- To describe the imaging features of vocal cord paralysis
- To describe the potential effects and the respective imaging features of laryngeal trauma
- To list the imaging features, causes and clinical consequences of tracheal stenoses
- To describe the imaging features of laryngoceles and pharyngoceles, webs and strictures
- To describe functional abnormalities of the larynx and hypopharynx during impaired swallowing including primary and secondary aspiration and dysfunction of the crico-pharyngeal muscle
- To describe the imaging features and clinical features of cervical esophageal carcinoma
- To describe the imaging features and clinical features of a Zenker diverticulum and the typical approaches to therapy
- To be familiar with PET-CT findings in head and neck tumours involving the pharynx, larynx and oral cavity.



Concerning the **thyroid and parathyroid gland**, candidates should be able:

- To describe the imaging and clinical features of thyroiditis
- To describe the imaging and clinical features of multinodular goiter
- To describe the imaging and clinical features of benign and malignant neoplasms of the thyroid and parathyroid glands, including thyroid and parathyroid adenomas, different types of thyroid carcinoma, and thyroid lymphoma
- To be familiar with the most important findings of Tc-99m-scintigraphy and PET/CT in various diseases of the thyroid gland.

Concerning the **congenital and transspatial lesions**, candidates should be able:

- To have a basic understanding of the embryology of the head and neck region
- To describe the imaging features and clinical features of branchial cleft cysts
- To describe the imaging features and clinical features of thyroglossal duct cysts
- To describe the imaging features and clinical features of thymus cysts
- To describe the imaging features and clinical features of vascular lesions including malformations of the head and neck region
- To be familiar with the imaging manifestations of neurocutaneous syndromes, including neurofibromatosis type I, in the head and neck region
- To describe the imaging features and clinical features of fibromatosis colli.

## Examination structure

The examination consists of a written and oral part. Both parts must be passed with at least 70% correct answers for the written exam and at least 2 out of 3 well-solved oral cases, respectively. The detailed instructions for the examination are included in Appendix 3. The candidates will be examined by head and neck radiology experts nominated by the Educational Committee of the ESHNR.

The **written exam** lasts 75 minutes and includes four types of questions:

- Multiple choice questions
- Normal / normal variant versus abnormal
- Annotate the structures
- Short cases

The topics that will be examined include normal anatomy, imaging techniques and pathologic conditions involving the:

- Petrous bone, the skull base and cranial nerves,

- Orbit and visual pathways
- Sinuses, the face and the deep spaces of the suprahyoid neck
- Oral cavity, the pharynx and the larynx,
- The neck, including lymph nodes and its vasculature and the deep spaces of the infrahyoid neck
- The salivary glands
- The mandible and temporomandibular joints
- The thyroid gland and the parathyroid glands, the thoracic inlet and the brachial plexus

The **oral exam** lasts 45 minutes oral examination and includes:

- 3 cases (15 minutes / case)

The candidate is expected to be able to describe the relevant findings and discuss them with the examiners, provide a differential diagnosis and discuss possible treatment options or further diagnostic tests. The most important part of the oral examination is that the candidate shows that he / she is able to analyse the case appropriately and provide a suitable differential diagnosis.

Both written and oral examinations are in the English language.

A representative of the ESR will be present as an observer during the written and oral exam.

## Terminology

Successful candidates will be awarded the European Board of Head and Neck Radiology Diploma. In addition, they become Fellows of the ESHNR. The Fellow status is valid for as long as the Diploma is valid.

## Appendix 1

### The anatomic areas covered by head and neck radiology

1. The petrous bone, the skull base and cranial nerves,
2. The orbit and visual pathways
3. The sinuses, the face and the deep spaces of the suprahyoid neck
4. The oral cavity, the pharynx and the larynx,
5. The neck, including lymph nodes and its vasculature and the deep spaces of the infrahyoid neck
6. The salivary glands
7. The mandible and temporomandibular joints
8. The thyroid gland and the parathyroid glands, the thoracic inlet and the brachial plexus

## Appendix 2

### **Courses and meetings recognized by the Educational Board of the ESHNR in view of the European Board in Head and Neck Radiology Diploma**

General guidelines:

- All courses recognised for the diploma are organised or co-organised by active and internationally recognized members of the ESHNR
- All courses are accredited by the UEMS and / or by the national radiological societies
- For meetings and courses that deal only in part with head and neck radiology, only the lectures on head and neck topics are recognized for the curriculum (see above)
- For all ongoing courses of the respective calendar year, the organiser of the course makes sure that the detailed course program is available via links from the website of the society for online consultation
- One course hour = 1 point. A total of at least 100 points are required for the diploma. All or only part of the necessary 100 points may be acquired by attending the below specified courses. Certificates of attendance are required for documentation
- The webinars of ESHNR count for the diploma (1 webinar with MCQ = 1 point)

Recognised annual courses and meetings:

- Annual Meeting and Refresher Course of the ESHNR
- Educational ESHNR webinars
- ERASMUS Course on Head and Neck
- Advanced Head and Neck MR Imaging organized by the ESMRMB
- Refresher Courses on head and neck radiology at the ECR in Vienna
- Refresher Courses on head and neck radiology at the RSNA in Chicago
- Diplôme Inter Universitaire (DIU) ORL organized by the CIREOL / SFR (100 points)
- Journées Francophones de Radiologie in Paris
- Annual Meeting and Refresher Course of the ASHNR
- Symposia of the CIREOL

Additional recognised courses and meetings:

- GALEN Advanced Course ESOR on Head and Neck Imaging
- Leuven Course on Ear Imaging
- Leuven Course on Head and Neck Cancer Imaging
- HNO Radiology: Part I Face
- HNO Radiology: Part II Temporal bone
- HNO Radiology: Part III Neck
- International Diagnostic Course Davos: Diseases of the Brain, Head and Neck and Spine
- Swiss Forum Head and Neck Diagnostics
- Sandwichcursus Neuro- en Hoofd-Hals Radiologie

## Appendix 3

### Written examination example

- Multiple choice questions

Q1. Which of the following statements is correct?

Laryngeal cancers involving the epiglottis

- A. are more aggressive than piriform sinus cancers
- B. very often invade the arytenoid and cricoid cartilages
- C. are seen more often in females than in males
- D. very often invade the preepiglottic space.

Correct answer: D.

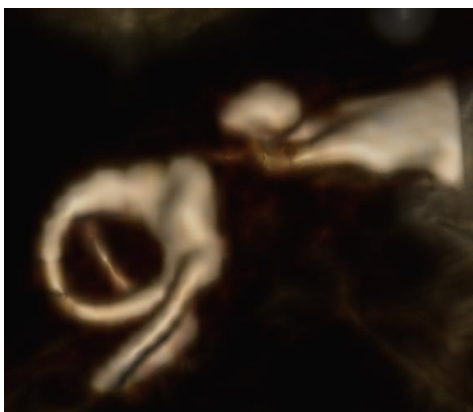
Q2. A 39-year old patient with a history of sinusitis treated with antibiotics since 5 days by the family physician presents with fever, leukocytosis, facial swelling and erythema in the emergency department. No neurologic deficit. Which is the examination method of choice?

- A. No radiologic exam needed
- B. Conventional X rays of the paranasal sinuses
- C. Contrast enhanced CT
- D. Unenhanced low-dose CT

Correct answer: C.

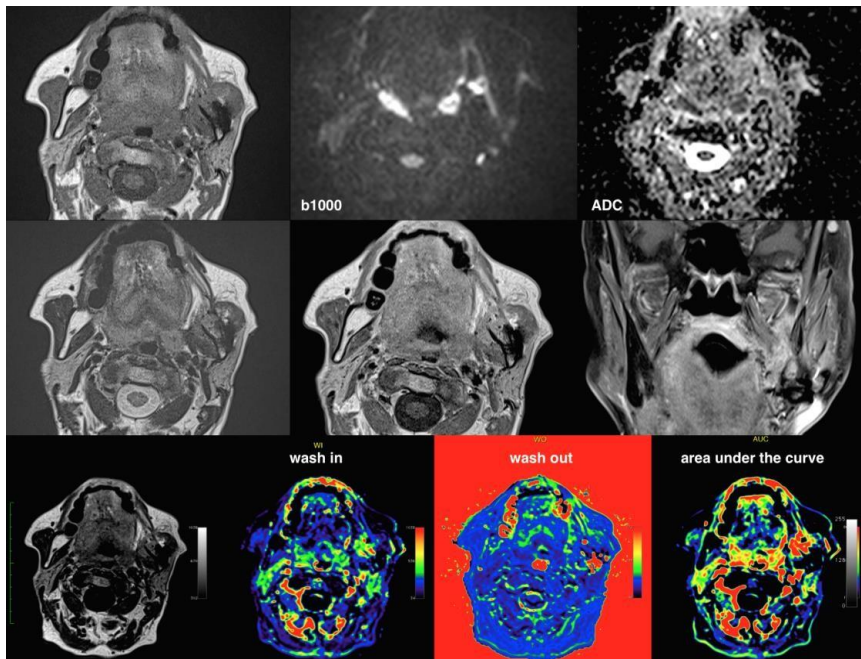
- Normal / normal variant versus abnormal

Q3. 3D Volume rendering of the inner ear of a 1year old male images for SNHL. Indicate whether it is normal or abnormal and if abnormal provide the diagnosis



Correct answer: Abnormal, cochlear hypoplasia

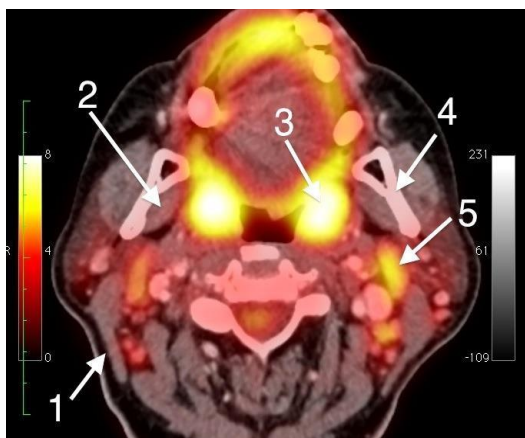
Q4. MRI of a 66-year old male obtained 2 years after radiotherapy for a head and neck squamous cell carcinoma of the oral cavity. Indicate whether it is normal or abnormal and if abnormal provide the diagnosis.



Correct answer: Abnormal, recurrent cancer with mandibular invasion on the left

- Annotate the structures

Q5. Name the anatomic structures 1- 5 on the following PET CT image.





**eshnr**

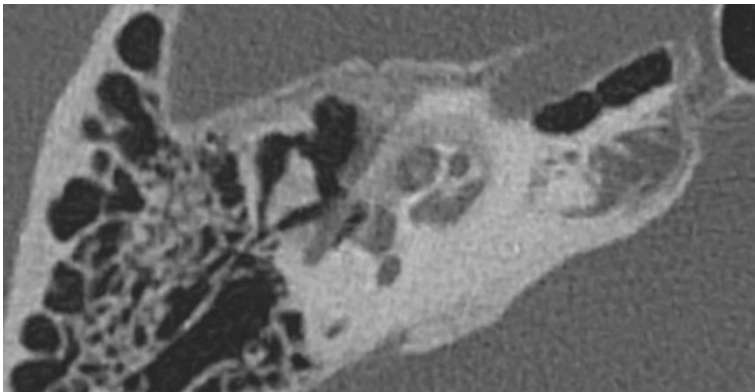
European Society of  
Head and Neck Radiology

Correct answer:

1. Sternocleidomastoid muscle
2. Internal pterygoid muscle
3. Palatine tonsil
4. Ascending ramus of the mandible
5. Level II lymph node

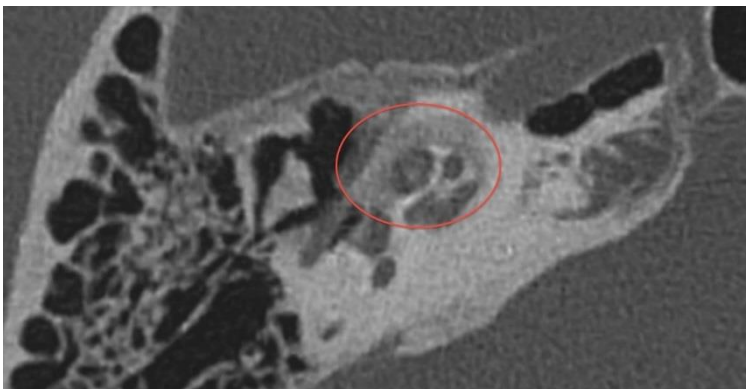
- Short cases

Q6. 50-year old patient of Caucasian origin presenting with bilateral mixed hearing loss, on the right more pronounced than on the left. No neurologic deficit. Medical history: hypertension under treatment. The patient has spent several years in Congo as a child. Since over 20 years has been living in Switzerland. A CT of the temporal bone was performed.



1. Indicate the abnormality on this CT image by means of a circle.

Correct answer:



**European Society of Head and Neck Radiology**

Am Gestade 1 | 1010 Vienna | Austria

Phone: +43 1 5334064-918 | E-mail: office@eshnr.eu

www.eshnr.eu | ZVR 421925549

2. What is your differential diagnosis? (at least 2)

Correct answer: Otospongiosis, tuberculosis, syphilis

3. What is the most likely diagnosis?

Correct answer: Otospongiosis

### **Oral examination details**

The oral examination includes 3 cases from different anatomic regions of the head and neck area as follows:

- one case head and neck oncology,
- one case skull base /temporal bone and
- one case on any other area/topic (salivary glands, neck, thyroid, paranasal sinuses, TMJ, etc).

The cases will be presented in a DICOM format or a Power-Point format by the examiners and the candidate is asked to comment / discuss the cases as she / he would do it during clinical routine work.

The candidate is expected to be able to describe the relevant findings and discuss them with the examiners, provide a differential diagnosis and discuss possible treatment options or further diagnostic tests. The most important part of the oral examination is that the candidate shows that he/ she is able to analyse the case appropriately and provide a suitable differential diagnosis.

During the entire examination a representative of the ESR will be present as an observer. The examination language is English. Therefore, knowledge of the English language (understanding of written and spoken language as well as knowledge of English medical terminology) is required.