

**eshnr**

European Society of  
Head and Neck Radiology

**ESHNR 2020 Online Teaching Weeks**  
20 hours of on-demand education  
October 24 to December 7

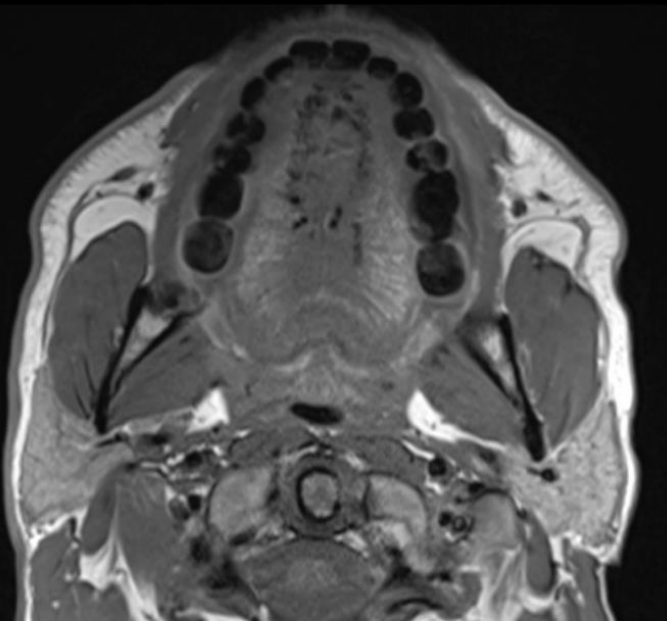
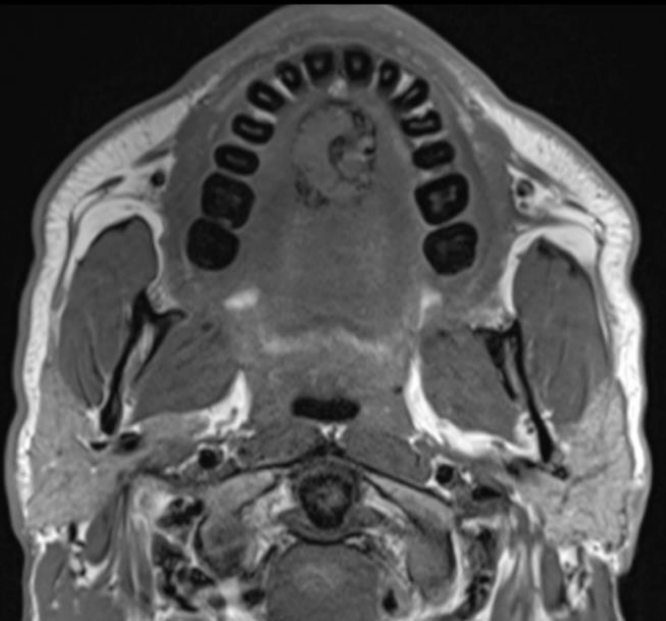
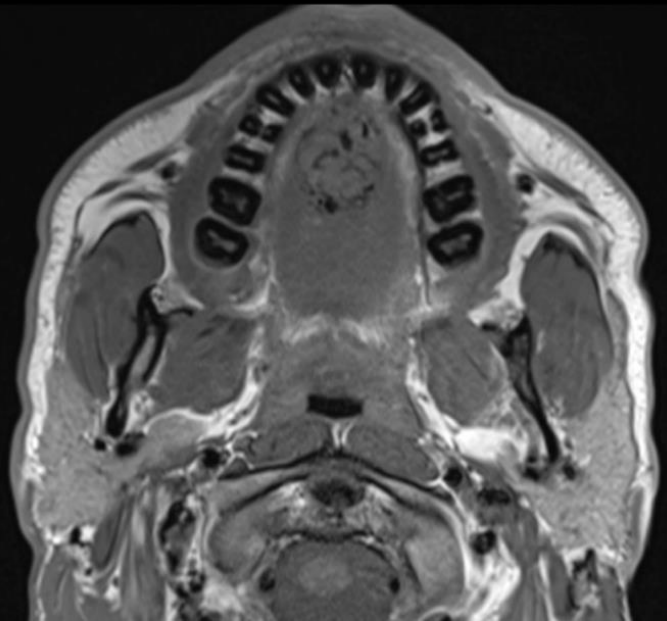
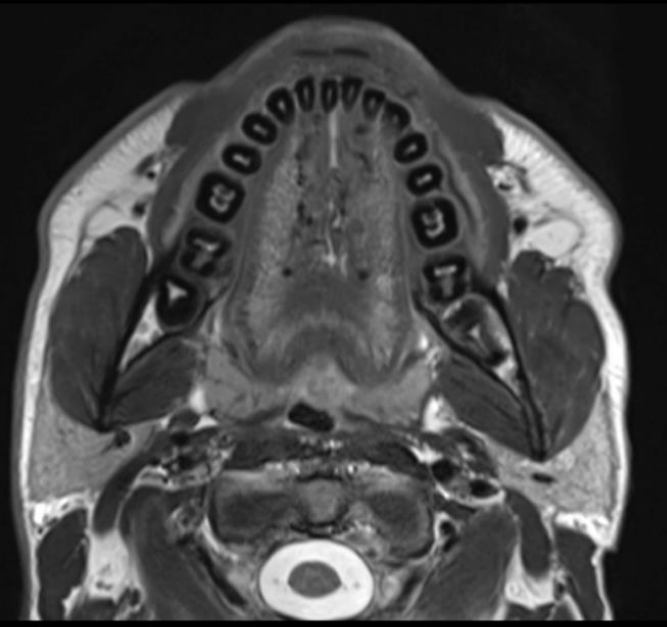
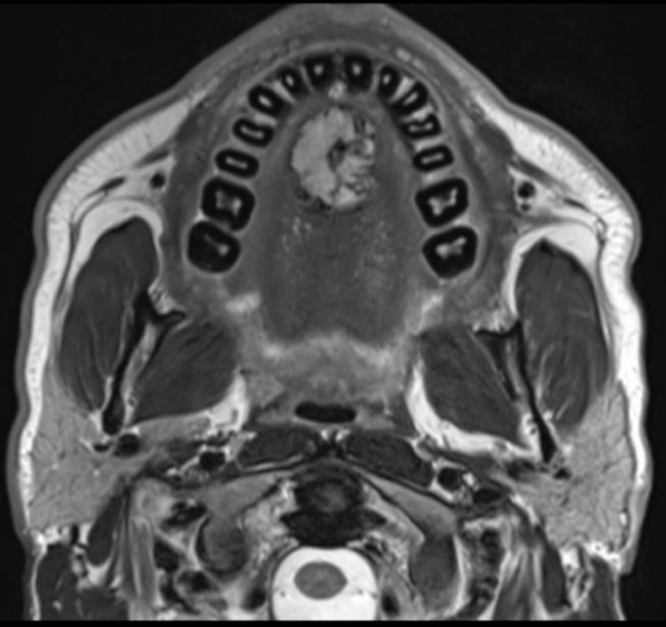
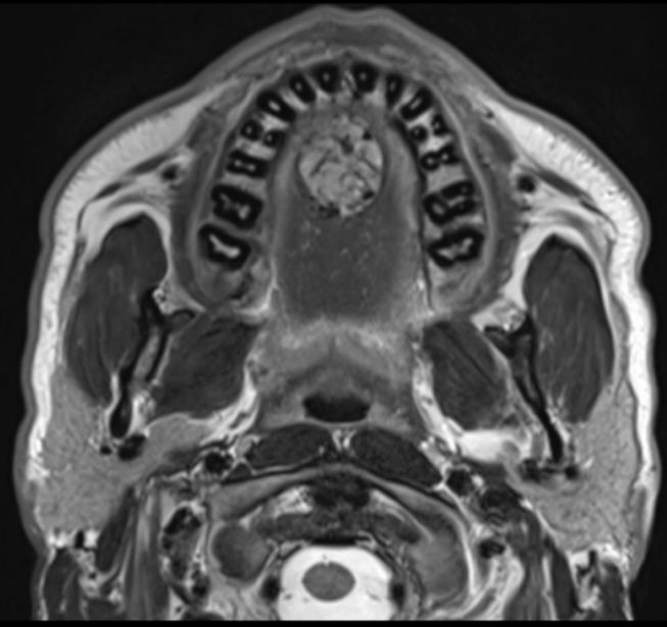


# **Tough & ... not so tough head & neck cases**

## **CASE 4**

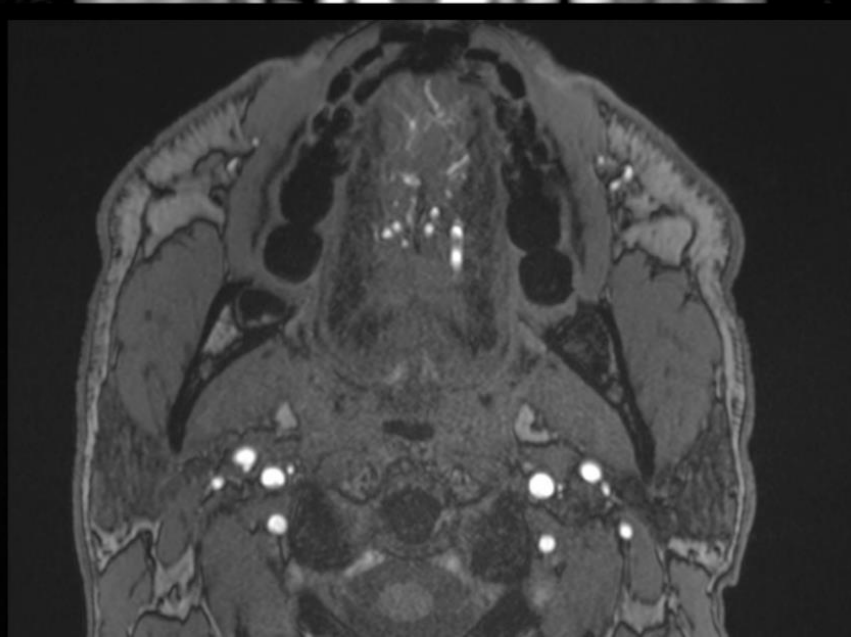
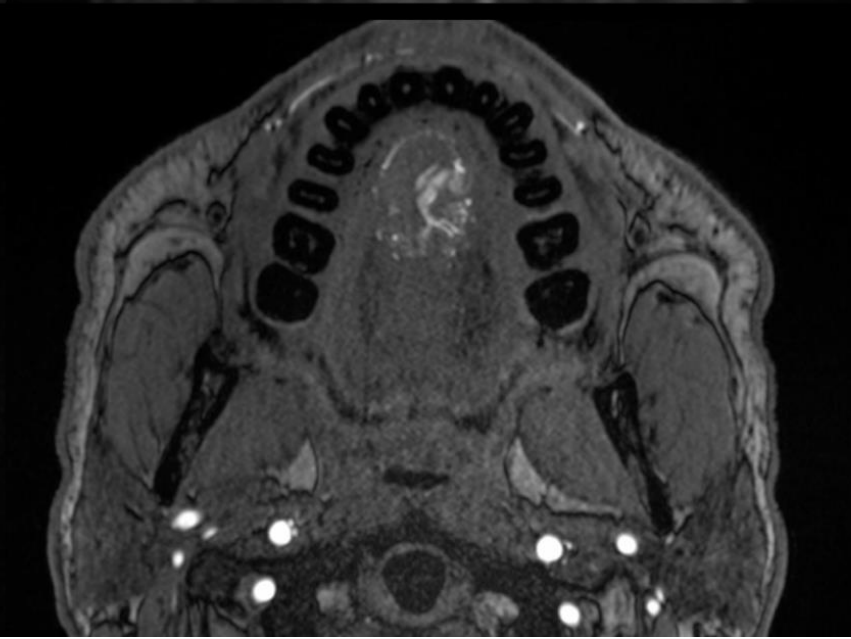
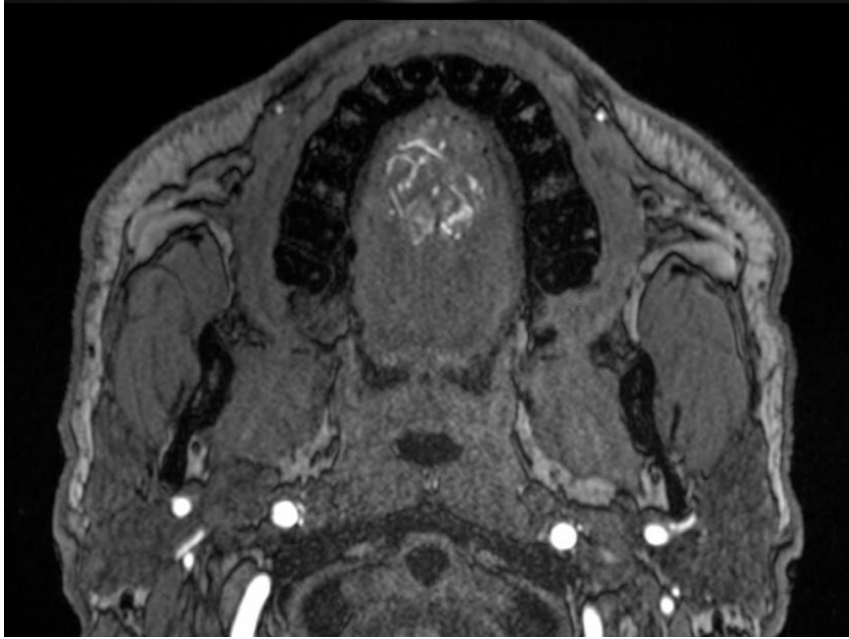
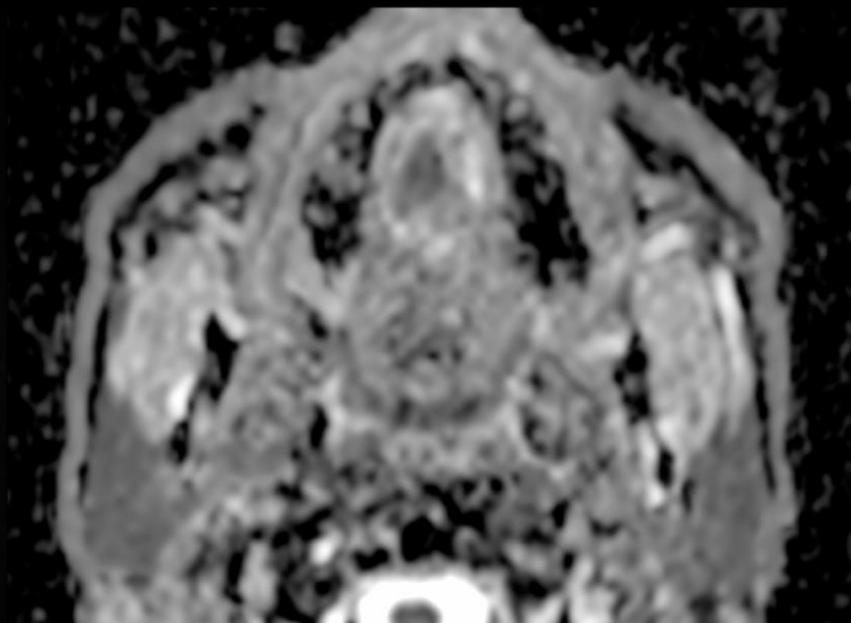
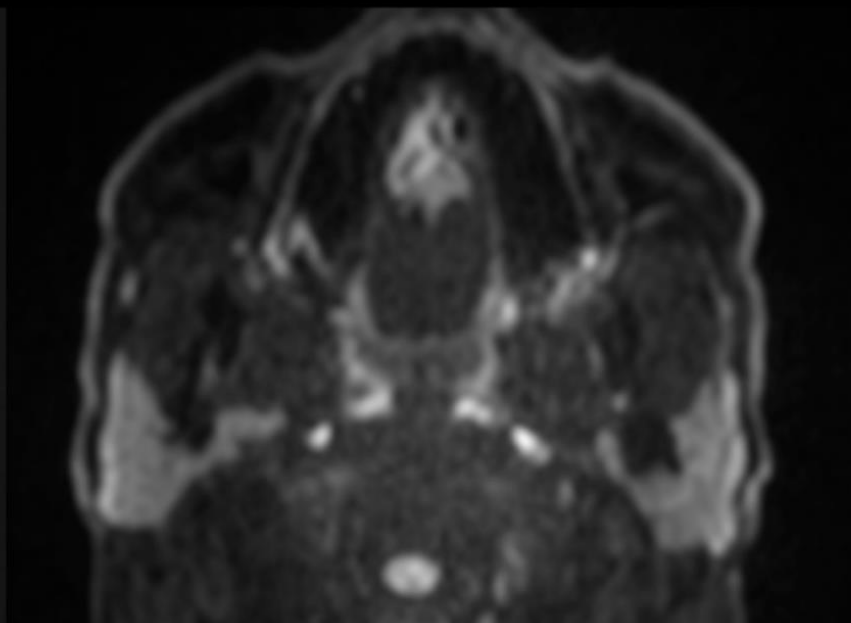
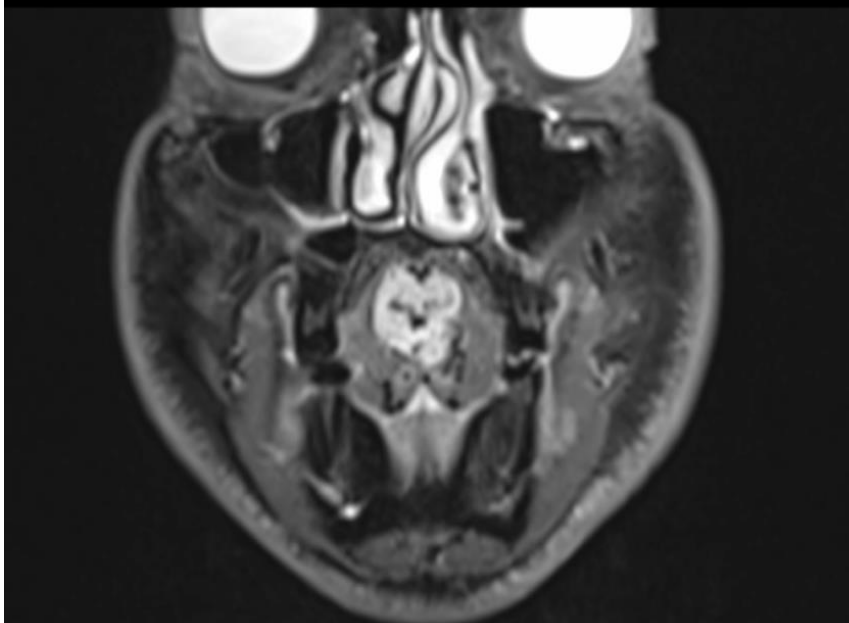
**41-year-old male patient with palpable tongue induration. No mucosal superficial lesion was seen. MRI was obtained. Enclosed are representative images. What is your diagnosis / differential diagnosis?**

CASE 4 : MRI

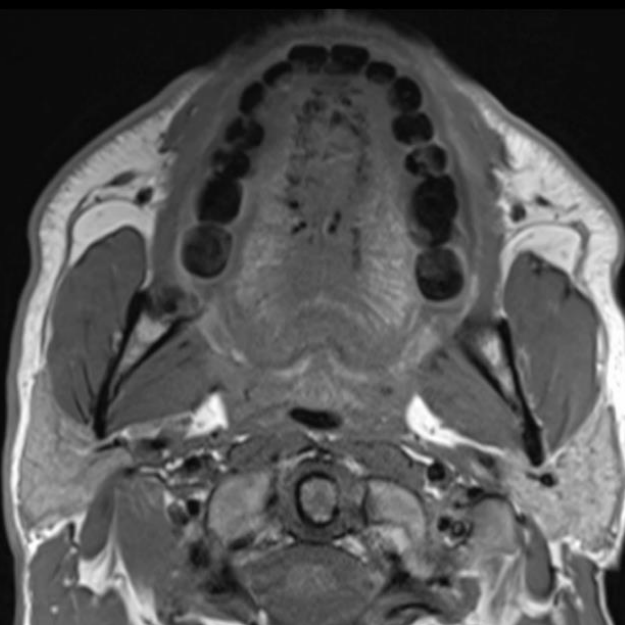
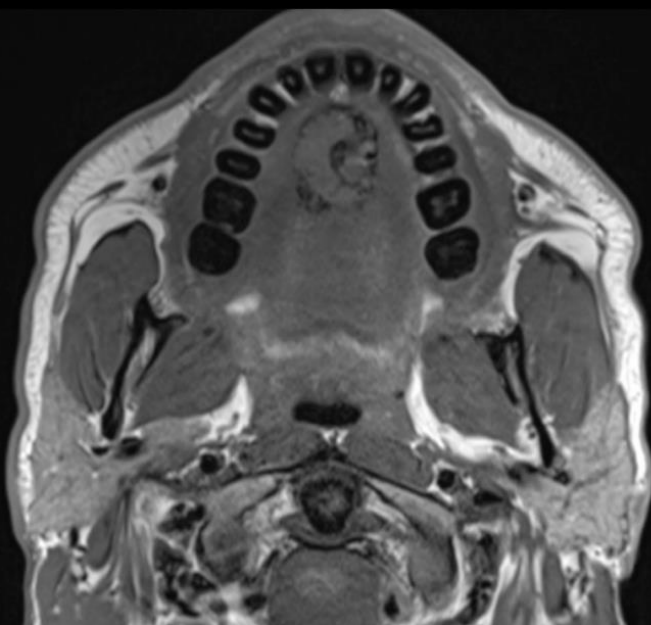
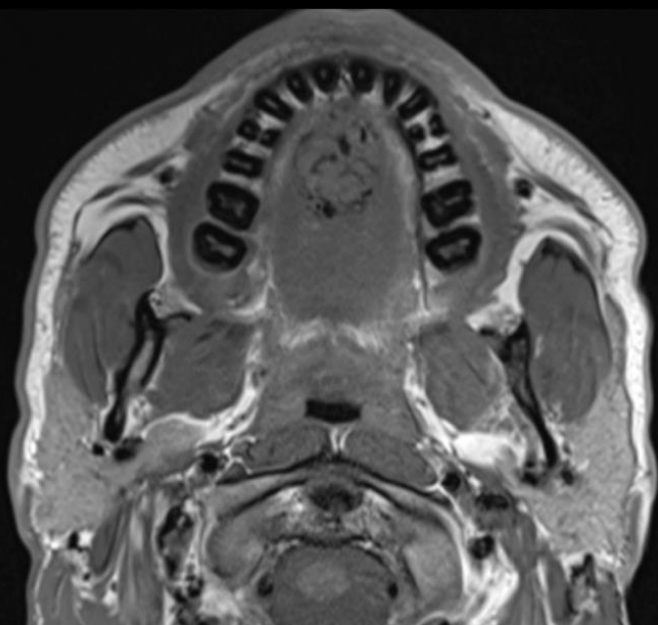
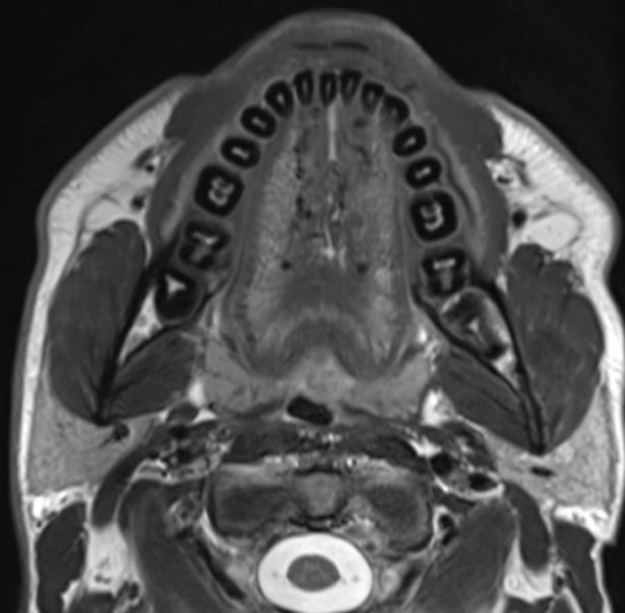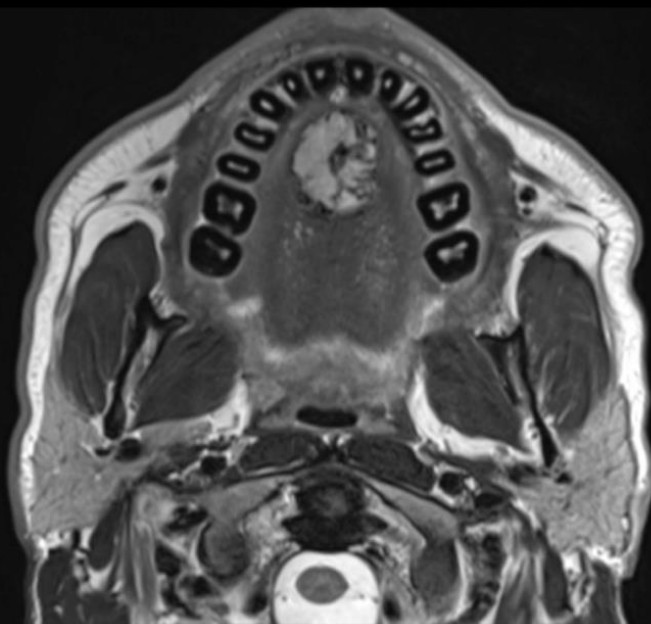
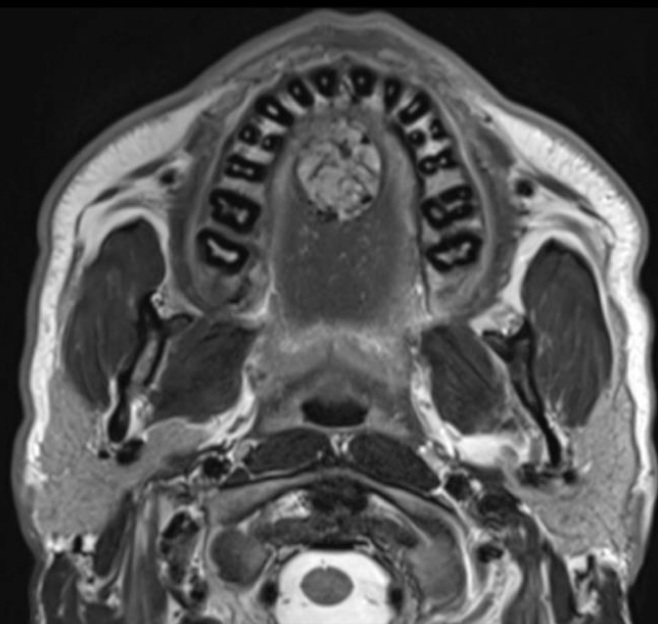




# CASE 4 : MRI



# CASE 4 : MRI



# CASE 4 : MRI

